


Allevio migränkateter

CureMed
NORDIC

När ingenting annat hjälper




Allevio är framtagen för att lindra **migränanfall**,
Hortons huvudvärk och **Trigeminusneuralgi**.


Utvecklad i USA där behandlingen är etablerad.

Behandlingen är helt smärtfri och enkel att utföra.

Inga biverkningar.

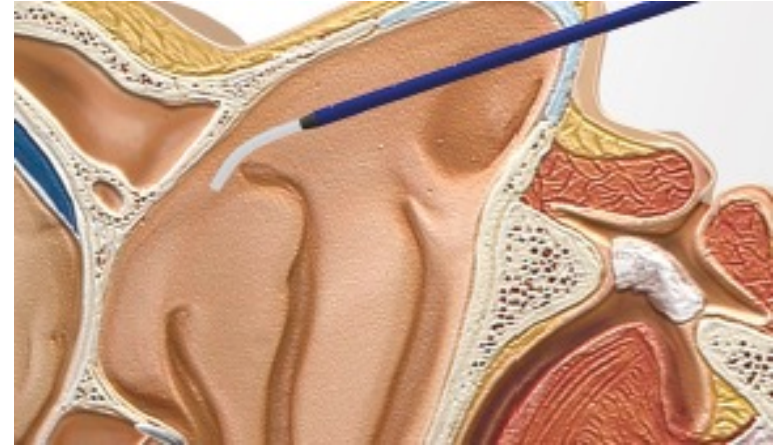


- Allevio – migränkateter består av två stycken plastkatetrar införda i varandra.
- Vid användning böjs den inre katetern automatiskt så att den kommer in i näsans bakre del.
- Genom katetern injiceras 4% lokalbedövningsmedel, typ Lidokain.
- Allevio – migränkateter är CE-godkänd som medicinteknisk produkt och enkel att använda.




Instruktion

1. Patienten ligger ner på brits/säng
2. Allevio – migränkateter förs in i ena näsborren tills det tar stopp
3. Dra tillbaka katetern 5 mm (en halv markering märkt på katetern)
4. Tryck in den inre katetern som då kommer att hamna automatiskt i hålrummet
5. Injicera 2 ml 4% lokalbedövningsmedel genom katetern
6. Dra ut katetern
7. Gör samma procedur i andra näsborren.
8. Patienten skall ligga kvar i ryggläge i ca 10 minuter



Hur ofta bör behandlingen genomföras?

- Enligt erfarenheter från sjukhus i USA så har man börjat med att ge behandlingen 2 gånger i veckan under en 3 veckors period.
- Efter ett tag så har man ökat på behandlingen eller minskat frekvensen.
- En del patienter får omedelbar effekt av behandlingen och andra tar lite längre tid.



Studier

Ny behandling för barn med migrän

- Omkring 12 procent av barn över elva år är drabbade av migrän.
- En studie vid ***Society of Interventional Radiology*** visar att SPG-blockad är lika säker och effektiv för barn som för vuxna.
- Studien gjordes 2015 på 85 patienter mellan 7 och 18 år.
- Medelvärdet på patienternas smärtskala före behandling var 5,55 och efter bedövningen 3,28. Inga komplikationer rapporterades.
- Metoden kan innebära ett minskat användande av intravenös läkemedelsbehandling.

<https://www.lakemedelsvarlden.se/ny-behandling-for-barn-med-migran/>

LmV.

LäkemedelsVärlden. Oberoende om läkemedel.

Studier

Utvärdera effekten av SPG-blockad som behandling för kronisk huvudvärk på 112 patienter med en medålder på 45 år.

- Medelvärde på patienternas smärtskala före behandling var 8,25. Efter avslutad behandling på 30 dagar var resultatet nere på 5,25
- 88% av patienterna behövde mindre medicin för smärtlindring efter behandlingen.



[https://www.jvir.org/article/S1051-0443\(14\)01349-9/fulltext](https://www.jvir.org/article/S1051-0443(14)01349-9/fulltext)

S40 ■ Sunday

Scientific Session ■ JVIR

antibiotics greater than one hour prior to the procedure. None of the doses were ordered by the interventional radiologist. No patients had post-procedural complications of fever, bacteremia, sepsis, or hemorrhage.
Conclusion: CT-guided abdominal or pelvic abscess drainage can be performed safely without peri-procedural antibiotic administration.

Scientific Session 8

MSK/Spine II

Sunday, March 1, 2015
5:00 PM – 6:00 PM
Room: 303

5:00 PM

Abstract No. 77

■ FEATURED ABSTRACT

Image-guided sphenopalatine ganglion blocks: an IR solution for chronic headaches
K. Mandato¹, G. Siskin¹, D. Geer², R. Tartaglione¹, G. Bolotin¹, C. Stavrakis¹, M. Englander¹, L. Keating¹, A. Herr¹; ¹Radiology, Albany Medical Center, Albany, NY; ²SUNY Empire State College, Saratoga, NY

Purpose: To evaluate the efficacy of image-guided intranasal sphenopalatine ganglion (SPG) blocks as treatment for chronic headaches.

Materials and Methods: A retrospective analysis of 112 patients (mean age: 44.5 years; 79%F; 21%M) was performed to assess changes in headache quality following an image-guided SPG block. All patients had migraine or cluster headaches as defined by the International Headache Classification and a stable medication regimen for >7 days. They had no history of psychiatric illness, surgery, or anatomical cause for headaches. All patients were assessed with a visual analogue scale (VAS), ranging from 1-10, to quantify the degree of debilitation. Using fluoroscopy, a 4F Allevio SPG catheter (Jet Medical, Schwenksville, PA) was positioned above the middle turbinate via an intranasal approach and directed toward the SPG. The ganglion was outlined with contrast. 2 cc of 4% Xylocaine was administered during nasal inhalation. This was then repeated in the opposite nostril. The patients remained supine for five minutes before discharge. Follow-up VAS assessments were made on post-procedure day 1, 7, and 30.

Results: At baseline, the mean VAS score was 8.25. All patients had a VAS score >4 for at least 15 days of every month. Following the procedure, this decreased to 4.10 (p<0.001) on day 1, 4.40 (p<0.001) on day 7, and 5.25 (p<0.001) on day 30; this represented a 36% reduction in VAS score at day 30. Seven patients (6.3%) failed to respond to treatment. 88% of patients required less medication for ongoing pain relief.

Conclusion: Image-guided SPG blocks can diminish the pain and disability associated with chronic headaches and has the potential to be an alternative to traditional therapy. 4% Xylocaine is required to penetrate the mucosal barrier surrounding the ganglion. Xylocaine's efficacy is due to inhibition of lipid bilayer depolarization preventing the migraine stimulus from completing the neurologic circuit that leads to the headaches. Results may improve with future catheter modifications, use of medications that may produce a more permanent block without compromising safety and better patient selection criteria. A blinded prospective study is recommended for further evaluation.

5:09 PM

Abstract No. 78

Percutaneous ultrasonic fasciotomy: a novel approach to treat chronic plantar fasciitis
R. Razdan, E. Vanderwoude; Radiology, Saint Elizabeth's Medical Center, Walton, NE

Purpose: Chronic plantar fasciitis, or fasciopathy, is the most common debilitating foot complaint, affecting approximately 10% of the population and accounting for over one million office visits annually. Many cases are refractory to nonoperative intervention, and recurrence is common. Consequently, safe and effective definitive treatments are desirable. The purpose of this presentation is to discuss our initial experience with percutaneous ultrasonic fasciotomy in the treatment of chronic, refractory plantar fasciitis.

Materials and Methods: Chronic plantar fasciopathy is a degenerative condition characterized histologically by disorganized collagen fibers, increased ground substance, hypercellularity, and neovascularity in the absence of inflammatory cells. The clinical diagnosis is based on the palpable plantar heel pain over the plantar fascia origin with ultrasound correlation demonstrating thickening, hypoechoogenicity, and heterogeneity of the plantar fascia. The differential diagnosis may include: calcaneal stress fracture, fat pad atrophy, and regional neuropathy. Using ultrasound guidance, a percutaneous ultrasonic fasciotomy was performed with the TX1 device (Tenex Health), which when activated, the hollow 18g needle tip emulsifies tissue using high frequency, low amplitude motions. Tissue is extracted via a fluid inflow-outflow pump.

Results: We treated 65 patients at our IR pain clinic between August 2013 until the present with chronic, refractory, plantar fasciopathy using ultrasonic fasciotomy. All patients had failed medications, activity modification, physical therapy, and arch supports. Foot and Ankle Disability Index (FADI) score were collected pre-procedure, and 2 weeks, 6 weeks, and 6 months post-procedure. Average Treatment time with the TX1 was 99 sec, with standardized post procedure rehabilitation. FADI scores demonstrated greater than 90% improvement in symptoms at two weeks and were maintained at 6 months (p < 0.0001). The patients were extremely satisfied with no procedure related complications.

Conclusion: Percutaneous ultrasonic fasciotomy is safe and highly effective at intermediate term follow up to treat chronic plantar fasciopathy. Long-term outcome studies are in progress.

Övriga gjorda studier med goda resultat

A New Look at Sphenopalatine Ganglion Blocks for Chronic Migraine

This simple, inexpensive procedure may provide a relatively low-risk option for the treatment of chronic migraines.

By [Kellie Spector, BS](#) and [Soma Sahai-Srivastava, MD](#)

Migraine is a common cause of disability leading to significant financial, societal, and personal burden, along with a diminished quality of life.^{1,2} According to the World Health Organization, migraine ranks in the top 20 causes of disability worldwide and accounts for 1.3% of life-years lost to disability.³ Migraine is 2 to 4 times more prevalent in women than men and disability from migraine is also more common in women.⁴ Chronic migraine became an established diagnosis in 2004 by the International Classification of Headache Disorders, and the criteria for diagnosing chronic migraine have been refined twice since then.⁵ Chronic migraine is currently defined as headache occurring on 15 or more days per month for more than 3 months, which has the features of migraine headache on at least 8 days per month.⁶ Compared with episodic migraines, chronic migraines cause a larger disease burden, increased healthcare utilization, and more associated comorbidities.⁷ In the United States, approximately 1% of the population (3 million people) suffers from chronic migraine.⁸ Most of the treatments aimed at migraines focus on management of high frequency episodic migraines.⁹ Despite its burden, clinical trials of pharmacological treatments for preventative or acute treatment for chronic migraines are lacking, with established treatments often ineffective or cause notable side effects (ie, medication overuse headache).⁹ When pharmacological interventions fail, patients often receive onabotulinumtoxin A injections (Botox), the only FDA-approved preventative treatment for chronic migraine.¹⁰ Other options include greater occipital nerve blocks.¹¹ The most severe and debilitating cases of chronic migraine sometimes require surgery, including occipital nerve stimulation or deep brain stimulation.¹² One procedure that has recently re-emerged in migraine treatment is the sphenopalatine ganglion (SPG) block.¹³⁻¹⁵ This procedure was first described in 1908 by Greenfield Sluder, MD, chairman of Otolaryngology at Washington University in St. Louis.¹³ The SPG contains postganglionic sympathetic fibers, synapses between pre- and postganglionic parasympathetic fibers, and somatosensory fibers of the head and neck region, making it a good target for pain intervention.¹⁴

Image-guided treatment shown to break the migraine cycle

Date: March 1, 2015

Source: Society of Interventional Radiology

Summary: An innovative interventional radiology treatment has been found to offer chronic migraine sufferers sustained relief of their headaches, according to new research. Clinicians have used a treatment called image-guided, intranasal sphenopalatine ganglion blocks to give patients enough ongoing relief that they required less medication to relieve migraine pain.

An innovative interventional radiology treatment has been found to offer chronic migraine sufferers sustained relief of their headaches, according to research being presented at the Society of Interventional Radiology's Annual Scientific Meeting. Clinicians at Albany Medical Center and the State University New York Empire State College in Saratoga Springs used a treatment called image-guided, intranasal sphenopalatine ganglion (SPG) blocks to give patients enough ongoing relief that they required less medication to relieve migraine pain.

"Migraine headaches are one of the most common, debilitating diseases in the United States, and the cost and side effects of medicine to address migraines can be overwhelming," said Kenneth Mandato, M.D., the study's lead researcher and an interventional radiologist at Albany Medical Center. "Intranasal sphenopalatine ganglion blocks are image-guided, targeted, breakthrough treatments. They offer a patient-centered therapy that has the potential to break the migraine cycle and quickly improve patients' quality of life," he added.

Mandato and his team conducted a retrospective analysis of 112 patients suffering migraine or cluster headaches. Patients reported the severity of their headaches on a visual analogue scale (VAS), ranging from 1-10, to quantify the degree of debilitation experienced from the migraine. During the treatment, which is minimally invasive and does not involve needles touching the patient, researchers inserted a spaghetti-sized catheter through the nasal passages and administered 4 percent lidocaine to the sphenopalatine ganglion, a nerve bundle just behind the nose associated with migraines.

Before treatment, patients reported an average VAS score of 8.25, with scores greater than 4 at least 15 days per month. The day after the SPG block patients' VAS scores were cut in half, to an average of 4.10. Thirty days after the procedure, patients reported an average score of 5.25, a 36 percent decrease from pretreatment. Additionally, 88 percent of patients indicated that they required less or no migraine medication for ongoing relief.

"Administration of lidocaine to the sphenopalatine ganglion acts as a 'reset button' for the brain's migraine circuitry," noted Mandato. "When the initial numbing of the lidocaine wears off, the migraine trigger seems to no longer have the maximum effect that it once did. Some patients have reported immediate relief and are making fewer trips to the hospital for emergency headache medicine," he said. Because of the minimally invasive nature of the treatment and the medication's safety profile, Mandato believes patients can have the SPG block repeated, if needed.

From the American Migraine Foundation

Sphenopalatine Ganglion Blocks in Headache Disorders

SEPTEMBER 4, 2016

[Facebook](#)[Twitter](#)[Google+](#)[Share](#)

The **Sphenopalatine Ganglion (SPG)** is a group of nerve cells that is linked to the trigeminal nerve, the main nerve involved in headache.

The SPG, located behind the nose, carries information about sensation, including pain, and also plays a role in autonomic functions, such as tearing and nasal congestion.

To read more about the SPG and its role in headache, please see these articles:

- [The Sphenopalatine Ganglion \(SPG\) and Headache Disorders, Part I](#)
- [The Sphenopalatine Ganglion \(SPG\) and Headache Disorders, Part II](#)

The link between the SPG and the trigeminal nerve is important in head pain. If you apply local anesthetics (or numbing medications) to block or partially block the SPG, this can be helpful in reducing head and facial pain.

SPG blocks were first described in the 1900's using a technique involving the application of numbing medication onto cotton swabs then placed into the back of the nose. Another technique used to block the SPG involves using a needle to inject the SPG through an area on the cheek. This process is invasive, and usually requires the use of an x-ray machine to place the injection correctly.

In the last few years, three devices have been FDA approved for performing SPG blocks.

These devices involve placing a very thin plastic tube into the nose to insert numbing medication in and around the SPG. These devices, called catheters, may be more effective in reducing head and facial pain than the technique using cotton swabs and are less invasive than the injection technique.

A New Look at Sphenopalatine Ganglion Blocks for Chronic Migraine

SPG Block Study Mandato MD

Sphenopalatine Ganglion Blocks in Headache Disorders

Allevio migränkateter

CureMed Nordic AB är ett svenskt medicintekniskt företag med huvudkontor och lager i Göteborg.

I vårt sortiment finner ni världsledande produkter inom sjukvård och medicinteknik varav många kan produceras kundanpassat.

Vårt mål är att alltid erbjuda sjukvården innovativa produkter från ledande producenter på ett kostnadseffektivt sätt.

